



## PATIENT

Pyper Hetherington

## SPECIES

Canine

## BREED

Portugese WaterHound

## SEX

Female Spayed

## AGE

9 years

## WEIGHT

63.3lbs

## INTERPRETED BY

Maggie Machen Lamy,  
DVM, DACVIM  
(Cardiology)

## IMAGING PERFORMED BY

Mark van Campen,  
DVM

## HOSPITAL NAME

Mississippi Hills  
Animal Hospital

## REFERRING VET

Dr. van Campen

## INVOICE

23338

## DATE

3/29/22

## PRESENTING CLINICAL SIGNS

History: Recheck echo. No clinical signs – may be slowing down a little.

-Current medications: Apoquel , Vetmedin 7.5 mg BID.

-Pertinent previous echo findings (9/2021 MML): Moderate MR, mild LAE, mild LVE. FS: 26%, LV; 4.7/3.5, LA: 3.1.

## ECHOCARDIOGRAM FINDINGS

2D, m-mode, color flow and doppler imaging is available. Diffuse thickening of mitral valve leaflets (anterior>posterior) with minimal prolapse into the left atrial lumen. Moderate eccentric mitral regurgitation with mild left atrial dilation. Normal MR velocity. Mildly increased LV diameter with borderline myocardial function. The tricuspid valve appears subjectively normal, with no tricuspid regurgitation. Normal right atrial and ventricular diameter. The pulmonic and aortic valves are normal in morphology and mobility. Normal pulmonic and aortic outflow velocities. No aortic or pulmonic insufficiency. No pericardial or pleural effusion noted. No cardiac tumors observed.

## CARDIAC CHART

CANINE CARDIAC PARAMETERS	MR VMAX (m/s)	TR VMAX (m/s)	LA/AO (Boon method)	LA/AO (Heart Base; Swe)	FS (%)	EF (%)	EPSS (cm)
NORMAL PARAMETER	4.5-5.5	<2.7	1.3	<1.6	28-40	40-100	<0.6
PATIENT	6.0	NA	NM	1.4	27	50	NM
CANINE CARDIAC PARAMETERS	HR (BPM)	AV VMAX (m/s)	PV MAX (m/s)	BODY WEIGHT (kg)	LA 2D short axis Base view (cm)	LVIDd Avg: 2D and m-mode short axis (cm)	LVIDs Avg: 2D and m-mode short axis (cm)
NORMAL PARAMETER	50-100	0.7-1.7	0.7-1.6	BELOW	BELOW	BELOW	BELOW
PATIENT	NM	1.8	1.2	28.7	3.7	4.8	3.5
*Normal chamber parameters expressed as a mean value (SD)				3	1.27 (5.3)	2.46 (2.46)	1.36 (5.5)
<b>BODY WEIGHT DEPENDENT PARAMETERS</b>				5	1.40 (4.5)	2.74 (5.2)	1.60 (4.7)
<i>*Note: All measurements based upon multi-modal images and methods. An average value is reported.</i>				10	1.50 (3.8)	3.27 (3.5)	2.06 (3.1)
				15	1.83 (2.0)	3.71 (2.4)	2.43 (2.1)
				20	2.02 (1.9)	4.14 (2.2)	2.80 (2.0)
				25	2.18 (2.4)	4.48 (2.9)	3.10 (2.5)
				30	2.33 (3.3)	4.83 (3.9)	3.39 (3.4)
				35	2.48 (4.3)	5.17 (5.0)	3.69 (4.5)
				40	2.62 (5.2)	5.48 (6.1)	3.96 (5.4)
				50	2.88 (7.1)	6.07 (8.3)	4.46 (7.4)

## INTERPRETATION OF THE FINDINGS & FURTHER RECOMMENDATIONS

Stable disease persists in this study. While the LA dimension is slightly increased comparatively, the overall ratio remains only mildly dilated. The LV is similar to previous with borderline function and mildly increased dimensions. No obvious additional issues are identified.

Given these findings, no change to the current medications is recommended. Continued assessment of progression in the future will help predict long term outcome, however prognosis remains guarded at this stage (B2).



### PATIENT

Pyper Hetherington

### SPECIES

Canine

### BREED

Portugese  
WaterHound

### SEX

Female Spayed

### AGE

9 years

### WEIGHT

63.3lbs

### INTERPRETED BY

Maggie Machen Lamy,  
DVM, DACVIM  
(Cardiology)

### IMAGING PERFORMED BY

Mark van Campen,  
DVM

### HOSPITAL NAME

Mississippi Hills  
Animal Hospital

### REFERRING VET

Dr. van Campen

### INVOICE

23338

### DATE

3/29/22

Omega fatty acid supplementation and mild salt restriction may also be of some long-term benefit. Monitor for development of a progressive cough, labored breathing, exercise intolerance or collapse episodes.

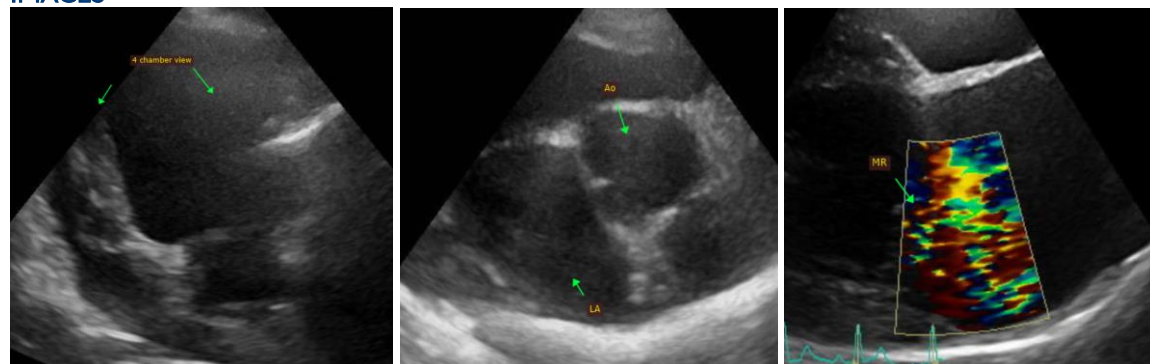
Anesthetic risk is considered mildly elevated. Cardiac protective drug choices (opioid/benzodiazepine premedication, Propofol or alfaxalone induction, iso or sevo gas) are recommended. Monitor for arrhythmias, hypotension, and hypoxia both intra and post-operatively and intervene as necessary. Judicious IV fluid rates are recommended to avoid fluid overload. Avoid heart rate stimulating drugs such as atropine unless clinically indicated.

### PLAN

Monitor BP every 6 months. Continue Pimobendan as prescribed.

Recommend monitor for progression with a recheck echocardiogram in 6-12 months, sooner if any development of clinical signs.

### IMAGES



The information and recommendations provided are based on the images presented by the referring veterinarian. No evaluation can be communicated regarding pathology that was not visible in the image/video clips provided.

Thank you for this referral. This report was generated using transcription software, and minor dictation errors may be present. If the clinical or image interpretation does not parallel your findings or if I can be of any further assistance, please contact me.

Maggie Machen Lamy, DVM  
Diplomate of the American College of Veterinary Internal Medicine (Cardiology)  
info@sonopath.com



**PATIENT**

Pyper Hetherington

**SPECIES**

Canine

**BREED**

Portugese  
WaterHound

**SEX**

Female Spayed

**AGE**

9 years

**WEIGHT**

63.3lbs

**INTERPRETED BY**

Maggie Machen Lamy,  
DVM, DACVIM  
(Cardiology)

**IMAGING  
PERFORMED BY**

Mark van Campen,  
DVM

**HOSPITAL NAME**

Mississippi Hills  
Animal Hospital

**REFERRING VET**

Dr. van Campen

**INVOICE**

23338

**DATE**

3/29/22